Earn
4 CEUs
This course was written for dentists, dental hygienists, and assistants.

Minimally Invasive Tissue Management for Restorative Procedures

A Peer-Reviewed Publication
Written by Stephen Poss, DDS

ADA C·E·R·P Continuing Education Recognition Program
The Academy of Dental Therapeutics and Stomatology is an ADA CERP Recognized Provider

PennWell®

dental CE digest®

www.INEEDCE.com
1-888-INEEDCE
The Academy of Dental Therapeutics and Stomatology

This course was made possible through an unrestricted educational grant. The cost of this CE course is $59.00 for 4 CEUs.
Cancellation/Refund Policy: Any participant who is not 100% satisfied with this course can request a full refund by contacting the Academy of Dental Therapeutics and Stomatology in writing.

Educational Objectives

1. Know the factors and considerations in the placement of direct and indirect restorations.
2. Understand the reasons and pre-requisites for the successful sub-gingival placement of restoration margins.
3. Be knowledgeable concerning the various methods of gingival retraction that are available, and factors in selecting a method.

Abstract

The clinical success and longevity of restorations depend on a number of factors, including the initial accuracy of the restoration. Factors attributed to restoration accuracy have included the degree of clinical expertise; properties of impression, stone and die, and restorative materials; and the conditions under which impressions are taken and restorations completed. When restorations are placed with sub-gingival margins, it is essential that the operative site is clear of debris, dry and that the margins are accessible. This requires gingival retraction, which can be carried out using a number of methods, including retraction cord, copper bands, rubber dams, electrosurgery, and lasers, as well as polymers and pastes. Selection of the appropriate method depends on clinical demands and preferences, the individual patient, and consideration of the potential advantages and disadvantages. Ideally, gingival retraction should be quick, user-friendly, patient-friendly, painless, and inexpensive. The use of modern techniques and materials has made possible minimally-invasive and tissue-friendly gingival retraction that preserves periodontal health while enabling clear, dry access to sub-gingival margins.

Introduction

The clinical success and longevity of restorations depend on a number of factors. Although recurrent or secondary caries has been found to be a major reason for the replacement of existing restorations,[1] the materials and techniques employed at the time of restoration are key considerations in determining longevity and clinical success for both direct and indirect restorations. Factors attributed to restoration accuracy, depending on the type of restoration (direct or indirect), have included the degree of clinical expertise; properties of impression, stone and die, and restorative materials; and the conditions under which impressions are taken and restorations completed.

Restoration accuracy and longevity

Indirect restorations

Indirect restoration accuracy is influenced by a number of material and technique considerations. Impression material, setting accuracy, flow, temperature and humidity, mixing, disinfection, and time-to-pour following impression-taking have all been investigated. Polyether impressions have been shown to absorb water; their post-impression dimensional stabilities – and therefore the accuracy of the model – were found in an in vitro study to decrease with increasing humidity and higher temperatures.[2] Other studies, however, have found that the presence of water does not adversely affect dimensional accuracy of either polyether or polyvinylsiloxane impression materials, but found that polyether has a greater likelihood of producing superior impressions when water is present.[3] Studies have also found that use of appropriate agents for disinfection immersion results in polyether, polyvinylsiloxane, and addition-cured silicone impressions that have a clinically-acceptable accuracy post-immersion.[4,5] Hand-mixing and cartridge-mixing have been shown to affect shrinkage of set impressions over time, with more shrinkage occurring at extended time intervals prior to model and die-pouring.[6] Another investigation found that the investment material and number of sprues used influences the dimensional accuracy of cast restorations.[7] In addition to these considerations, the selection of restorative material must take into account occlusal forces, any paranormal habits, and the space available for the restoration vis-à-vis material strength and depth/volume. (Table 1)

Table 1. Considerations – direct and indirect restorations

Direct
- Biologic width
- Esthetics
- Restorative material(s)
- Occlusal forces and paranormal habits
- Dry, clean and accessible field for restoration placement
  - — Gingival retraction for detailed impression
  - — Hemostasis
- Technique

Indirect
- Biologic width
- Esthetics
- Restorative material(s)
- Occlusal forces and paranormal habits
- Impression material properties
- Temperature, humidity
- Disinfection of impressions
- Mixing method
- Elapsed time prior to model-pouring
- Dry, clean and accessible field for impression-taking and restoration placement
  - — Gingival retraction for detailed impression
  - — Hemostasis
- Technique
- Investment material, number of sprues

Supra-gingival restoration margins may be considered preferable for periodontal health but are frequently esthetically unacceptable and/or may be impossible due to pre-existing hard-tissue loss. As a result, restorations are placed with margins sub-gingivally in the gingival sulcus – the objectives are to achieve a long-lasting restoration that

optimizes esthetics, has good marginal accuracy, maintains biologic width, and preserves periodontal health.

While the properties and selection of materials are important, margins that are free of debris, are accessible, and which impression materials can flow over and around, are a pre-requisite for detailed and accurate impressions and, ultimately, clinically-acceptable indirect restorations. Investigators have also found that the width of the gingival sulcus influences impression accuracy, with a sulcus width of more than 0.15 mm resulting in accurate impressions, and those less than 0.10 mm resulting in variable outcomes.[8]

Direct restorations

Similar considerations exist for direct class V restorations with respect to restorative material selection and technique, as well as esthetics and hard-tissue loss pre-determining sub-gingival placement of restorative margins. These, too, should respect biologic width, periodontal health, esthetics, and marginal accuracy.

Figure 1. Sub-gingival Class V carious lesion

It is critical when placing composite restorations that the field is dry to enable placement of the restoration and curing of composites. Successful placement of direct composite restorations is not possible without adequate curing. Furthermore, the degree of cure of the composite material is a determinant for leakage and marginal breakdown; one in vitro study has shown that enhanced curing reduces marginal breakdown and increases resistance to wear.[9] Gingival retraction and isolation of the operative site are essential for sub-gingival direct restoration placement and a biologically and esthetically compatible form.[10]

Gingival retraction and soft-tissue management

Regardless of all other considerations, accurate recording and restoration of sub-gingival margins is imperative for direct and indirect restorations. Optimal gingival retraction is essential.[11] Appropriate retraction enables clear visualization of the prepared tooth's sub-gingival margin; allows for accurate impression-taking apical to the margin with adequate impression material bulk between the sulcular wall and the tooth; controls crevicular seepage and bleeding; and, depending upon the preparation design, may help provide access to sub-gingival hard-tissue that must be treated due to caries or retentive/esthetic considerations.[12]

A number of retraction methods have been used, including retraction cords with and without medicaments, rotary curettage, copper bands, rubber dams, electrosurgery, lasers, and, recently, polymers and pastes. Each method offers the clinician the ability to perform gingival retraction, with selection of the appropriate method depending on clinical demands and preferences, the individual patient, and consideration of the potential advantages and disadvantages. Ideally, gingival retraction should be quick, user-friendly, patient-friendly, painless, and inexpensive – and importantly, tissue-friendly to preserve periodontal health.

Retraction cord

Retraction cords have been used for several decades and have traditionally been the most popular method. As recently as 1999, a survey of prosthodontists found that 98 percent of respondents used gingival retraction cords, with 44 percent of them using a double-cord technique.[13]

When used appropriately, retraction cord offers a quick, familiar, and inexpensive retraction method. It can be carried out with or without the addition of hemostatic agents, using either a single-cord or a double-cord technique. The double-cord technique uses two cords packed successively, with the first cord remaining in place while the impression is taken, prior to being removed. This technique is used for troughing around the preparation, to help ensure a detailed impression as well as an adequate biologic width of the final restoration.[14] It employs two knitted cords of different diameters and is considered safe and effective, provided periodontal health is good. However, it has also been recommended that where possible, the finish lines should be placed supra-gingivally when using this method.[15] With the single-cord technique, a single retraction cord is placed in the sulcus and if an impression is being taken, the cord is removed prior to this occurring. A disadvantage of the single-cord technique is that if preparation margins are in a deep sulcular area, the gingival soft-tissue can collapse over the margins making accurate restoration placement or impression-taking impossible.

The use of gingival retraction cord is technique-sensitive and requires expertise. Problems encountered include the parting of cord fibers, shredding, and cord damage or displacement when using the packing instrument or while using a bur at the margin.[16] Tissue damage may also occur, with friable thin gingival tissue particularly susceptible and subject to tearing. While packing the cord, there is a risk of damaging the epithelial attachment and/or exacerbating gingival recession and bleeding. Retraction cord use can result in tissue recession, and the double-cord technique may cause unpredictable tissue recession and patient

discomfort.[17] A 2007 investigation has found that acute, gingival tissue damage occurs with use of retraction cords, with demonstrable increases in the levels of tumor necrosis factor (alpha) (TNF-alpha) in the gingival crevicular fluid. Nonetheless, the same study also found that the damage healed clinically within two weeks.[18]

The use of hemostatic agents with retraction cords helps prevent gingival bleeding that may occur during packing or removal of the cord[19] and helps maintain a clear, dry operative site for cord-packing and impression-taking. Hemostatic agents in retraction cords include epinephrine, aluminum chloride, and ferric sulfate and, depending upon the particular cord, it may have been pre-treated or soaked at the time of placement.[20,21] Aluminum chloride has been found to be more commonly used than epinephrine: 33 percent of respondents in one survey reported side effects associated with epinephrine use, the most common being an increased pulse rate, with 24 percent reporting side effects from other medicaments used with retraction cords.[22] Use of epinephrine provides prolonged gingival vasoconstriction, but the use of aluminum chloride and ferric sulfate has been associated with hyperemia and bleeding upon cord removal.[23] However, epinephrine use is problematic in patients with cardiovascular disease and may interact with cardiovascular medications used to control the disease.[24]

Copper bands and impression copings

The use of copper bands, as well as impression copings for cast restorations, results in isolation of the site and obviates the need for gingival retraction using retraction cord or other techniques. As with retraction cords, copper bands have been used for a number of decades. Their use requires selection of copper band size, and careful trimming and fitting of the copper band prior to impression-taking. (Figure 2) Copper bands are inexpensive, readily-available, and with appropriate use are unlikely to result in tissue damage and recession. However, this method is technique sensitive, and the sharp margins of the copper band may exacerbate gingival bleeding; the bands do not incorporate a hemostatic agent and can cause patient discomfort without the use of local anesthesia.

Figure 2. Copper band

Cast impression copings function similarly to copper bands, fitting over the preparation finish line. They do not require trimming, nor do they have the sharp margins associated with copper-band use; they can capture margins and provide accurate, detailed impressions without using gingival retraction. However, they must be individually fabricated, involving an extra step.[25] By their very nature, cast impression copings are only used for indirect restorations, and both these and copper bands are unsuitable for direct restorations.

Rubber dams

Rubber dams help prevent operative-site exposure to oral micro-organisms and intraoral fluids. By using modified retention and a modified technique with placement of the rubber dam apical to the retainer after the retainer has been positioned on the tooth, rubber dams have been found to be effective in providing gingival retraction and thorough isolation of Class V restorative sites with sub-gingival margins, and help avoid damage to periodontal tissues.[26,27] This technique is intended for class V restorations and is unsuitable for impression-taking and indirect restorations.

Rotary curettage

Rotary curettage uses burs to create a trough in the sulcus around the finish line. It can result in bleeding at the site, requires local anesthesia to prevent patients from experiencing discomfort, and can be used for both direct and indirect restorations.

Electrosurgery

Electrosurgery is a modified cautery technique, utilizing an electric current passed to fine wire contacts that removes soft-tissue and creates a trough in the gingival sulcus adjacent to the finish line. One study found no difference in tissue response at four, eight, and twelve weeks between electrosurgery and bur (rotary curettage) methods.[28] A separate study found both electrosurgery and rotary curettage produced unpredictable results.[29] With clinical expertise, this method offers predictable troughing and tissue responses, with good exposure of margins for impression-taking and restorative techniques. It has also been shown to provide for more impression material bulk in the sulcus than a bur method.[30] Electrosurgery requires local anesthesia, and in addition to exposing the finish line and creating a trough, it also helps prevent bleeding at the site (Figures 3 and 4).

Figure 3. Gingival bleeding, sub-gingival preparation margin

Image courtesy of Dr. Ian E. Shuman

Figure 4. Use of an electrosurgery tip (Bident) to expose margins, stop bleeding

Image courtesy of Dr. Ian E. Shuman

Lasers

The introduction of dental lasers has offered dental professionals many options in operative techniques, including their use as a gingival retraction method. Lasers produce a high-energy, collimated beam of light that is converted into thermal energy. They predictably vaporize tissue at 100 to 150 degrees Celsius, create an adequate trough and retraction that permits detailed and accurate impressions, and preserve biologic width. (Figures 5, 6, and 7) Erbium-based lasers are absorbed on the surface and the Nd:YAG series energy is absorbed deeper in the tissues.[31] A third type of laser, the diode laser (Odyssey, Vivadent), is also utilized for soft-tissue procedures. Their use results in minimal or no intra-operative and post-operative discomfort, and is not associated with tissue recession seen with the use of the double-cord gingival retraction method. In addition, lasers offer hemostasis and can be used in many patients without anesthesia.[32,33] In comparing the use of a pulsed Nd:YAG laser with retraction cord soaked in either aluminum chloride or ferric sulfate, it has also been found that the laser's use resulted in less bleeding, less tissue inflammation, faster healing than either retraction cord, and was painless, simple, and convenient. Laser use is suitable for both indirect and direct restorations in offices that have laser units.[34] In a survey of laser users, 79 percent of respondents indicated that they used lasers for gingival retraction/troughing.[35] Lasers, such as the Waterlase™ YSGG Laser (Biolase), also offer the potential to complete the hard-tissue preparation and soft-tissue management with one instrument and in some cases without the use of anesthesia.[36]

Figure 5. Crown preparation with bleeding, sub-gingival margins prior to impression-taking

Image courtesy of Dr. Glenn van As

Figure 6. Use of a diode laser (Odyssey, Vivadent)

Image courtesy of Dr. Glenn van As

Figure 7. Final impression showing clear margin details

Image courtesy of Dr. Glenn van As

Polymers and pastes

Polymers and pastes have also been recently introduced as gingival retraction methods. Studies have shown that the use of polymers with a sponge-like texture cut into 2-mm strips is an effective method. The polymer swells when exposed to moisture and gently pushes the gingival tissue away from the finish line, enabling detailed impression-taking. In addition, it was found that the gingivae returned to a normal position within twenty-four hours. [37] Merocyl strips were found to be effective at expanding gingival tissue and exposing the margins of preparations for impression-taking.[38]

A recent technique uses a paste (Expasyl™) that provides for gingival retraction and hemostasis. Expasyl™ consists of an organic, clay material (kaolin), mixed with aluminum chloride as a hemostatic agent. The paste is thick, firm, and viscous to enable easy and quick tissue displacement, and the aluminum chloride controls bleeding simultaneously. It is injected directly into the sulcus from a pre-loaded syringe at a recommended rate of 2 mm per second, using even pressure. (Figure 8) If necessary, this can be followed by gently tamping on the paste with a plastic instrument or cotton pellet to ensure the paste is fully in the sulcus. The paste is left in the sulcus for one to two minutes if the tissue is thin, or three to four minutes if the soft-tissue is thicker. After this time, the sulcus will be expanded, and the paste should be removed by gently rinsing and then drying the site prior to impression-taking or restoration placement. (Figure 9a and b)

Figure 8. Expasyl™ injected into the gingival sulcus

Figure 9a. After Expasyl™ removal

Figure 9b. After Expasyl™ removal

Once the material has been applied and absorbs moisture, there is no chemical reaction, material expansion, or trauma to the tissue; hemostasis is achieved, and the material should be isolated from additional moisture, such as saliva. If necessary, the process can be repeated without traumatizing the tissue.

This paste system is suitable for gingival retraction prior to impression-taking (Figure 10) and final indirect restoration placement. Gingival retraction will last for four minutes after the Expasyl™ has been rinsed and removed from the site.

Figure 10. Final impression with clear margin details

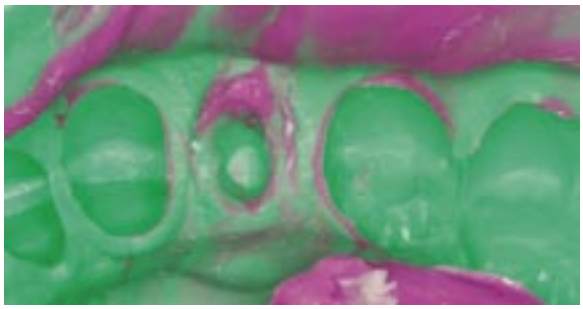

It can also be used prior to direct Class V restoration to prevent gingival seepage and bleeding, and to widen the sulcus, enabling a composite of the appropriate dimension to be placed and cured. (Figures 11 and 12)

Figure 11. Expasyl™ placement

Figure 12. Final direct composite restorations

Gingival retraction cord, electrosurgery, and laser surgery are more-traditional options. However, these result in varying degrees of tissue trauma, depending on clinical experience. The risk of gingival recession and bone resorption, linked to damage to the epithelial attachment, is eliminated using the minimally-invasive tissue management offered by the paste retraction method.[39] It has been found to reduce chairside time required for retraction prior to impression-taking and restoration placement, and reduces soft-tissue trauma as well.[40,41] Time savings of up to 50 percent have been reported with its use.

A polyvinylsiloxane expandable gingival retraction paste is available (Magic FoamCord Gingival Retraction System). This is also applied around the preparation margins using a pre-loaded syringe. After syringing the material around the margins, a cap (Comprecap) is used over the material and tooth – this is used to apply pressure for 5 minutes to obtain gingival retraction. The impression is

Table 2. Comparison of gingival retraction methods

	Application method	Traumatic to tissue	Requires pressure	Requires tray or cap	Provides hemostasis	Time taken
Retraction cord	Packing into sulcus	Yes	No	No	Yes/No	Up to 5 minutes
Copper band	Trim and apply band	Yes	No	No	Yes, by isolating site	Up to 5 minutes
Rubber dam	With clamp/floss	No	No	No	Yes, by isolating site	Up to 5 minutes
Rotary Curettage	Direct	Yes	No	No	No	Up to 5 minutes
Electrosurgery	Direct	Yes	No	No	Yes	3 to 5 minutes
Laser surgery	Direct	Yes	No	No	Yes	3 to 5 minutes
Gingival retraction paste						
Expasyl™	Syringe	No	No	No	Yes	2 to 4 minutes
Magic FoamCord	Syringe	No	Yes	Yes	No	5 minutes
GingiTrac™	Syringe	No	Yes	Yes	Yes/No	5 minutes

taken after the paste has been removed. This paste does not contain a hemostatic agent, and hemostasis must be obtained prior to applying the paste and cap.

A third gingival retraction paste system (GingiTrac™) also uses a pre-loaded syringe to apply the paste around the margins. The paste contains an astringent, and if necessary a hemostatic agent can be applied prior to the application of GingiTrac™. For single tooth use, a cap (GingiCap™) is used to apply pressure for up to 5 minutes after the paste has been applied. The cap is first filled with the paste, then placed over the tooth and paste syringed around the margins. (Figures 13 and 14) For multiple tooth preparations, a plastic tray is first used with a firm paste matrix over which the GingiTrac™ paste is syringed before the tray is placed over the arch and held in position for 3-5 minutes. For both single tooth and multiple tooth preparations, gingival retraction is achieved through the application of pressure prior. The paste is removed prior to impression-taking.

Figure 13. Application of retraction paste and cap

Figure 14. Preparation margins after removal of paste and cap.

Summary

The multi-faceted benefits and indications of tissue management render it an important process in assessing clinical success. Traditional gingival retraction methods include retraction cords, copper bands, electrosurgery and more recently laser surgery. In addition, pastes have been introduced that function as gingival retractors. Depending upon the paste system used, the time taken is typically 2 minutes for paste not requiring use of caps or a tray matrix (Expasyl™) and up to 5 minutes for paste systems using caps or trays to apply pressure (Magic FoamCord; GingiTrac™) In selecting a method for tissue management during restorative procedures, it is incumbent upon clinicians to consider the advantages and disadvantages of each method, the individual case and patient, and to strive for minimally-invasive methods that optimize the procedural site for impression-taking and restoration placement, while at the same time preserving periodontal health. Recent innovations have made minimally-invasive soft-tissue management an achievable reality during restorative procedures.

References

1 MacInnis WA, Ismail A, Brogan H. Placement and replacement of restorations in a military population J Can Dent Assoc. 1991 Mar;57(3):227–231.

2 Endo T, Finger WJ. Dimensional accuracy of a new polyether impression material. Quintessence Int. 2006;37(1):47–51.

3 Walker MP, Petrie CS, Haj-Ali R, Spencer P, Dumas C, Williams K. Moisture effect on polyether and polyvinylsiloxane dimensional accuracy and detail reproduction. J Prosthodont. 2005;14(3):158–163.

4 Jagger DC, Al Jabra O, Harrison A, Vowles RW, McNally L. The effect of a range of disinfectants on the dimensional accuracy of some impression materials. Eur J Prosthodont Restor Dent. 2004;12(4):154–160.

5 Wadhwani CP, Johnson GH, Lepe X, Raigrodski AJ. Accuracy of newly formulated fast-setting elastomeric impression materials. J Prosthet Dent. 2005;93(6):530–539.

6 Lampe I, Marton S, Hegedus C. Effect of mixing technique on shrinkage rate of one polyether and two polyvinyl siloxane impression materials. Int J Prosthodont. 2004;17(5):590.

7 Leal MB, Paulino SM, Pagnano VO, Bezzon OL. Influence of investment type and sprue number on the casting accuracy of titanium crown margins. J Prosthet Dent. 2006;95(1):42–49.

8 Baharav H, Kupershmidt I, Laufer BZ, Cardash HS. The effect of sulcular width on the linear accuracy of impression materials in the presence of an undercut. Int J Prosthodont. 2004;17(5):585–589.

9 Ferracane JL, Mitchem JC, Condon JR, Todd R. Wear and marginal breakdown of composites with various degrees of cure. J Dent Res. 1997;76(8):1508–1516.

10 Balanko M, Jordan RE. Gingivally submerged cervical erosion lesion a – clinical problem. J Esthet Dent. 1990;2(4):104–108.

11 Liebenberg, WH. Alternative gingival retraction techniques and isolation of the cervical lesion. JADA. 1993;124(10):92–102.

12 Laufer BZ, Baharav H, Langer Y. The closure of the gingival crevice following gingival retraction for impression making. J Oral Rehab. 1997;24(9):29–635.

13 Hansen PA, Tira DE. Current methods of finish-line exposure by practicing prosthodontists. J Prosthodont. 1999;8(3):163–170.

14 Scott A. Use of an erbium laser in lieu of retraction cord: a modern technique. Gen Dent. 2005;53(2):116–119.

15 Cloyd S, Puri S. Using the double-cord packing technique of tissue retraction for making crown impressions. Dent Today. 1999;18(1):54–59.

16 Sharma S, Kugel G. Tissue management: what's new. Contemp Esthet Restorat Pract. 2005:(1):42–43.

17 Scott A. Use of an erbium laser in lieu of retraction cord: a modern technique. Gen Dent. 2005;53(2):116–119.

18 Feng J, Aboyoussef H, Weiner S, Singh S, Jandinski J. The effect of gingival retraction procedures on periodontal indices and crevicular fluid cytokine levels: a pilot study. J Prosthodont. 2006;15(2):108–112.

19 Csillag M, Nyiri G, Vag J, Fazekas A. Dose-related effects of epinephrine on human gingival blood flow and crevicular fluid production used as a soaking solution for chemo-mechanical tissue retraction. J Prosthet Dent. 2007;97(1):6–11.

20 Fazekas A, Csempesz F, Csabai Z, Vag J. Effects of pre-soaked retraction cords on the microcirculation of the human gingival margin. Oper Dent. 2002;27(4):343–348.

21 Abdel Gabbar F, Aboulazm SF. Comparative study on gingival retraction using mechanochemical procedure and pulsed Nd = YAG laser irradiation. Egypt Dent J. 1995;41(1):1001–1006.

22 Hansen PA, Tira DE, Barlow J. Current methods of finish-line exposure by practicing prosthodontists. J Prosthodont. 1999;8(3):163–170.

23 Fazekas A, Csempesz F, Csabai Z, Vag J. Effects of pre-soaked retraction cords on the microcirculation of the human gingival margin. Oper Dent. 2002;27(4):343–348.

24 Bader JD, Bonito AJ, Shugars DA. A systematic review of cardiovascular effects of epinephrine on hypertensive dental patients. Oral Surg Oral Med Oral Pathol Oral Radiol Endod. 2002;93(6):647–653.

25 Vasilakis GJ, Vasilakis MD. Cast impression coping technique. Gen Dent. 2003;51(1):48–50.

26 Owens BM. Alternative rubber dam isolation technique for the restoration of Class V cervical lesions. Oper Dent. 2006;31(2):277–280.

27 Liebenberg WH. Rubber dam isolation of cervical lesions. Part 1: Alternative techniques which avoid injury to the periodontium. FDI World. 1994;3(5):17–18, 20.

28 DeVitre R, Galburt RB, Maness WJ. Biometric comparison of bur and electrosurgical retraction methods. J Prosthet Dent. 1985;53(2):179–182.

29 Coelho DH, Cavallars J, Rothschild EA. Gingival recession with electrosurgery for impression making. J Prosthet Dent. 1975;33(4):422–426.

30 DeVitre R, Galburt RB, Maness WJ. Biometric comparison of bur and electrosurgical retraction methods. J Prosthet Dent. 1985;53(2):179–182.

31 Chartrand A. Integrating laser dentistry into aesthetic dentistry. Oral Health. 2005 April; 13–18.

32 Scott A. Use of an erbium laser in lieu of retraction cord: a modern technique. Gen Dent. 2005;53(2):116–119.

33 Passes H, Furman M, Rosenfeld D, Jurim A. A case study of lasers in cosmetic dentistry. Curr Opin Cosmet Dent. 1995;92–99.

34 Abdel Gabbar F, Aboulazm SF. Comparative study on gingival retraction using mechanochemical procedure and pulsed Nd = YAG laser irradiation. Egypt Dent J. 1995;41(1):1001–1006.

35 Laser Dentistry Survey. Dental Products Report. March 2005.

36 Jacboson B, Berger J, Kravitz R, Patel P. Laser pediatric crowns performed without anesthesia: a contemporary technique. J Clin Pediatr Dent. 2003;28(1):11–12.

37 Ferrari M, Nathanson D. Tissue management and retraction technique combined with all-ceramic crowns: case reports. Pract Periodontics Aesthet Dent. 1995;7(3):87–94.

38 Ferrari M, Cagidiaco MC, Ercoli C. Tissue management with a new gingival retraction material: a preliminary clinical report. J Prosthet Dent. 1996;75(3):242–247.

39 Shannon A. Expanded clinical uses of a novel tissue-retraction material. Compend Contin Educ Dent. 2002;23(1 Suppl):3–6.

40 Pescatore C. A predictable gingival retraction system. Compend Contin Educ Dent. 2002;23(1 Suppl):7–12.

41 Poss S. An innovative tissue-retraction material. Compend Contin Educ Dent. 2002;23(1 Suppl):13–17.

Author Profile

Dr. Stephen Poss is a graduate of the University of Tennessee and maintains an aesthetic-based practice in Brentwood, Tennessee. Dr. Poss has directed numerous live patient continuums at various teaching institutes emphasizing anterior and posterior aesthetic dentistry since 1995. Dr. Poss is presently the Clinical Director at The Center for Exceptional Practices in Cleveland, Ohio. He is also on the editorial team of Reality publishing.

Dr. Poss lectures internationally on esthetic dentistry and TMD. He is an active consultant to several dental manufacturers in the area of new product development and refinement. He has had numerous articles published in the leading dental journals.

Disclaimer

The author(s) of this course has/have no commercial ties with the sponsors or the providers of the unrestricted educational grant for this course.

Reader Feedback

We encourage your comments on this or any ADTS course. For your convenience, an online feedback form is available at www.ineedce.com.

Questions

1. Considerations in the longevity and clinical success of restorations include _____.
   a. the materials employed
   b. the techniques employed
   c. the presence of a HEPA filter
   d. a and b

2. _____ is a factor in determining post-impression dimensional stability of impressions.
   a. Humidity
   b. Impression flow
   c. Mixing of impression material components
   d. All of the above.

3. Supra-gingival restoration margins _____.
   a. are preferable to sub-gingival restoration margins under all circumstances
   b. may be esthetically unacceptable
   c. may be impossible due to pre-existing hard-tissue loss
   d. b and c

4. Margins that are accessible and free of debris are a pre-requisite for detailed and accurate impressions.
   a. True
   b. False

5. Both direct and indirect restorations should respect _____.
   a. biologic width
   b. periodontal health
   c. esthetics
   d. All of the above.

6. _____ is a determinant for leakage and breakdown of composite margins.
   a. The choice of cavity liner
   b. The degree of cure of the composite material
   c. Using an impression material
   d. None of the above.

7. Appropriate gingival retraction _____.
   a. enables clear visualization of sub-gingival margins
   b. allows for accurate impression-taking
   c. controls crevicular seepage
   d. All of the above.

8. Gingival retraction methods include the use of _____ .
   a. gingival retraction cord
   b. polymers and pastes
   c. lasers
   d. All of the above.

9. A 1999 survey found that _____ of prosthodontists use gingival retraction cord.
   a. 35 percent
   b. 63 percent
   c. 98 percent
   d. 100 percent

10. Retraction using gingival retraction cord can be carried out _____.
   a. with or without the addition of hemostatic agents
   b. using a double-cord or single-cord technique
   c. more quickly than any other gingival retraction method
   d. a and b

11. The double-cord gingival retraction technique _____.
   a. is considered safe and effective provided periodontal health is good
   b. is clinically-proven to be the least time-consuming method of gingival retraction
   c. involves the use of two retraction cords placed into the gingival sulcus, one after the other
   d. a and c

12. The use of copper bands is _____.
   a. expensive, redundant and still always requires the use of retraction cord
   b. inexpensive, technique sensitive, and with appropriate use unlikely to result in tissue damage or recession
   c. the most popular method, used routinely in the dental office
   d. a and c

13. A modified rubber dam technique that involves placing the rubber dam apical to clamps after these are placed, is suitable for _____.
   a. crown and bridge preparation margins
   b. crown and bridge, and Class V restoration, preparations
   c. only Class V restorations
   d. None of the above.

14. With clinical expertise, electrosurgery offers _____.
   a. predictable troughing
   b. a predictable tissue response
   c. good exposure of margins
   d. All of the above.

15. Electrosurgery _____.
   a. exposes the preparation margins
   b. helps prevent bleeding at the site
   c. never requires anesthesia
   d. a and b

16. Lasers expose gingival margins by _____.
   a. abrading tissue
   b. vaporizing tissue
   c. eroding tissue
   d. None of the above.

17. At 150° Celsius, gingival soft-tissue is _____.
   a. molten
   b. calcified
   c. vaporized
   d. All of the above.

18. Lasers used for gingival retraction _____.
   a. offer hemostasis
   b. may be able to be used without anesthesia
   c. are suitable for both direct and indirect restorations
   d. All of the above.

19. A recently introduced paste (Expasyl™), used for gingival retraction, _____.
   a. is applied using a pre-loaded syringe
   b. provides hemostasis
   c. contains epinephrine
   d. a and b

20. The use of hemostatic agents in gingival retraction paste containing kaolin (Expasyl™) _____.
   a. is contraindicated
   b. controls bleeding
   c. ensures that pressure and hemostatic agents will be used to control bleeding
   d. b and c

21. Expasyl™ should remain in the sulcus while an impression is being taken.
   a. True
   b. False

22. Kaolin-containing gingival retraction paste _____.
   a. absorbs moisture after application and reacts chemically until it is removed
   b. does not react chemically after being applied
   c. absorbs moisture after application, and after this there is no chemical reaction
   d. is contraindicated if moisture is present

23. Polyvinylsiloxane gingival retraction paste _____.
   a. is applied using a pre-loaded syringe
   b. requires the application of a cap over the paste and pressure for gingival retraction
   c. does not contain a hemostatic agent
   d. All of the above.

24. Some of the gingival retraction pastes discussed in the article should remain in place while an impression is taken.
   a. True
   b. False

25. GingiTrac™ gingival retraction paste _____.
   a. is applied using a pre-loaded syringe
   b. requires the application of pressure for gingival retraction
   c. can only be used for single tooth preparations
   d. a and b

26. If using GingiTrac™, a tray loaded with a heavy matrix _____.
   a. is used with multiple-tooth preparations
   b. is never necessary
   c. involves the use of composition that must be heated prior to use
   d. a and c

27. Concerning the three paste methods for gingival retraction discussed in the article, _____.
   a. all contain a hemostatic agent
   b. all are equally quick to use
   c. all use pre-loaded syringes
   d. All of the above.

28. Expasyl™ has been found to be minimally-invasive, as have Magic FoamCord and GingiTrac™, and to eliminate the risk of damage to the epithelial attachment.
   a. True
   b. False

29. In assessing the various methods of gingival retraction, it is incumbent upon clinicians to _____.
   a. consider the advantages and disadvantages of each method
   b. consider the individual case and patient
   c. use a slow method to ensure adequate gingival retraction
   d. a and b

30. Recent innovations have made minimally-invasive tissue management during restorative procedures _____.
   a. achievable
   b. no longer a consideration
   c. take more time
   d. None of the above.

ANSWER SHEET

Minimally Invasive Tissue Management for Restorative Procedures

Name:

Title: Specialty:

Address: E-mail:

City: State: ZIP:

Telephone: Home ( ) Office ( )

Instructions to obtain dental continuing education credits: 1) Complete all information above. 2) Complete answer sheets in either pen or pencil. 3) Mark only one answer for each question. 4) Successful completion of this course will earn you 4 CEUs. 5) A blank duplicate answer sheet may be copied for additional course participants.

Mail completed answer sheet to

Academy of Dental Therapeutics and Stomatology

P.O. Box 116, Chesterland, OH 44026

(216) 398-7822

For IMMEDIATE results, go to www.ineedce.com and click on the button "ENTER Answers Online." Answer sheets can be faxed with credit card payment to (216) 255-6619, (440) 845-3447, or (216) 398-7922.

❑ Payment of $59.00 is enclosed. **(Checks and credit cards are accepted.)**

If paying by credit card, please complete the following:

❑ MasterCard ❑ Visa ❑ AmEx ❑ Discover

Acct. Number: _____

Exp. Date: _____

Course Evaluation

Please evaluate this course by responding to the following statements, using a scale of Excellent = 5 to Poor = 0.

1. How would you rate the objectives and educational methods?
   5 4 3 2 1 0
2. To what extent were the course objectives accomplished?
   5 4 3 2 1 0
3. Please rate the course content.
   5 4 3 2 1 0
4. Please rate the instructor's effectiveness.
   5 4 3 2 1 0
5. Was the overall administration of the course effective?
   5 4 3 2 1 0
6. How do you rate the author's grasp of the topic?
   5 4 3 2 1 0
7. Do you feel that the references were adequate?
   Yes No
8. Do you feel that the educational objectives were met?
   Yes No
9. If any of the continuing education questions were unclear or ambiguous, please list them.
   _____
10. Was there any subject matter you found confusing? Please describe.
    _____
11. Would you participate in a program similar to this one in the future on a different topic? Yes No
12. What additional continuing dental education topics would you like to see?
    _____

1.	Ⓐ	Ⓑ	Ⓒ	Ⓓ	16.	Ⓐ	Ⓑ	Ⓒ	Ⓓ
2.	Ⓐ	Ⓑ	Ⓒ	Ⓓ	17.	Ⓐ	Ⓑ	Ⓒ	Ⓓ
3.	Ⓐ	Ⓑ	Ⓒ	Ⓓ	18.	Ⓐ	Ⓑ	Ⓒ	Ⓓ
4.	Ⓐ	Ⓑ	Ⓒ	Ⓓ	19.	Ⓐ	Ⓑ	Ⓒ	Ⓓ
5.	Ⓐ	Ⓑ	Ⓒ	Ⓓ	20.	Ⓐ	Ⓑ	Ⓒ	Ⓓ
6.	Ⓐ	Ⓑ	Ⓒ	Ⓓ	21.	Ⓐ	Ⓑ	Ⓒ	Ⓓ
7.	Ⓐ	Ⓑ	Ⓒ	Ⓓ	22.	Ⓐ	Ⓑ	Ⓒ	Ⓓ
8.	Ⓐ	Ⓑ	Ⓒ	Ⓓ	23.	Ⓐ	Ⓑ	Ⓒ	Ⓓ
9.	Ⓐ	Ⓑ	Ⓒ	Ⓓ	24.	Ⓐ	Ⓑ	Ⓒ	Ⓓ
10.	Ⓐ	Ⓑ	Ⓒ	Ⓓ	25.	Ⓐ	Ⓑ	Ⓒ	Ⓓ
11.	Ⓐ	Ⓑ	Ⓒ	Ⓓ	26.	Ⓐ	Ⓑ	Ⓒ	Ⓓ
12.	Ⓐ	Ⓑ	Ⓒ	Ⓓ	27.	Ⓐ	Ⓑ	Ⓒ	Ⓓ
13.	Ⓐ	Ⓑ	Ⓒ	Ⓓ	28.	Ⓐ	Ⓑ	Ⓒ	Ⓓ
14.	Ⓐ	Ⓑ	Ⓒ	Ⓓ	29.	Ⓐ	Ⓑ	Ⓒ	Ⓓ
15.	Ⓐ	Ⓑ	Ⓒ	Ⓓ	30.	Ⓐ	Ⓑ	Ⓒ	Ⓓ

PLEASE PHOTOCOPY ANSWER SHEET FOR ADDITIONAL PARTICIPANTS.

AGD Code 250

AUTHOR DISCLAIMER

The author of this course has no commercial ties with the sponsors or the providers of the unrestricted educational grant for this course.

INSTRUCTIONS

Each question should have only one answer. Grading of this examination is done manually. Participants will receive verification in the mail within three to four weeks after taking an examination.

SPONSOR/PROVIDER

This course was made possible through an unrestricted educational grant from Kerr Corporation. No manufacturer or 3rd party has had any input into the development of course content. All content has been derived from the references listed and the opinions of clinicians. Please direct all questions pertaining to the ADTS or the administration of this course to the program director: P.O. Box 116, Chesterland, OH 44026, or e-mail aeagle@ineedce.com.

PARTICIPANT FEEDBACK

Questions can be e-mailed to aeagle@ineedce.com or faxed to (216) 255-6619, (440) 845-3447, or (216) 398-7922.

COURSE CREDITS/COST

All participants scoring at least 70% (answering 21 or more questions correctly) on the examination will receive verification of 4 CEUs. The formal continuing education program of this sponsor is accepted by the AGD for Fellowship/Mastership credit. For current terms of acceptance, please contact the ADTS. "DANB Approval" indicates that a continuing education course appears to meet certain specifications as described in the DANB Recertification Guidelines. DANB does not, however, endorse or recommend any particular continuing education course and is not responsible for the quality of any course content. Participants are urged to contact their state dental boards for continuing education requirements. The cost of this course is $59.00.

EDUCATIONAL DISCLAIMER

The information presented here is for educational purposes only. It may not be possible to present all information required to utilize or apply this knowledge to practice. It is therefore recommended that additional knowledge be sought before attempting a new procedure or incorporating a new technique or therapy. The opinions of efficacy or the perceived value of any products or companies mentioned in this course and expressed herein are those of the author(s) of the courses and do not necessarily reflect those of the ADTS.

RECORD KEEPING

The ADTS maintains records of your successful completion of any exam. Please contact our offices for a copy of your continuing education credits report. This report, which lists all credits earned to date, will be generated and mailed to you within five business days of receipt of your request.

CANCELLATION/REFUND POLICY

Any participant who is not 100% satisfied with this course can request a full refund by contacting the Academy of Dental Therapeutics and Stomatology in writing.

COURSE EVALUATION

We encourage participant feedback pertaining to all courses. Please be sure to complete the survey included within the answer sheet.

© 2007 by the Academy of Dental Therapeutics and Stomatology

TISMGT0705PAT